

## CASE REPORT

### A GIANT OSTEOCHONDROMA IN A BOY WITH MULTIPLE EXOSTOSES

**Kirovski I, Gucev ZS, Tasic V, Pop-Jordanova N**

<sup>1</sup>*University Children's Hospital, Medical Faculty Skopje, R. Macedonia*

**Abstract:** Hereditary multiple exostoses (HME) is an inherited autosomal dominant disorder characterised by the presence of multiple exostoses, in fact benign cartilaginous tumors (enchondromata on the long bones). A six-year-old boy was found to have multiple osteochondromas on the legs, arms and ribs. Unusually, one of the osteochondromas on the right arm was huge (5 × 6 cm) and painful. X ray confirmed the benign nature of the osteochondromas. The family history was uneventful as well as the pregnancy and delivery. His intelligence is normal, and ultrasound did not detect any anomalies of the heart or kidneys.

The occurrence of a large osteochondroma in a young boy is rare. In spite of its size and growth the lesion is so far benign. Frequent follow-up is recommended for the timely detection of eventual malignant transformation.

**Key words:** Multiple hereditary exostoses, giant osteochondromas.

#### *Introduction*

HME is a relatively rare disease with a prevalence estimated at 1 : 50,000. The highest frequency of HME is reported in the Chamorros of Guam estimated at 1 in 1,000 [1]. HME seems to be more frequent in males (male-to-female ratio 1.5 : 1).

It is of note that enchondromas develop and increase in size in the first decade of life, ceasing to grow when the growth plates close at puberty. They can vary widely in size and number within and between families. The mean number of locations is estimated to be 15–18. Long bones of the extremities, predomi-

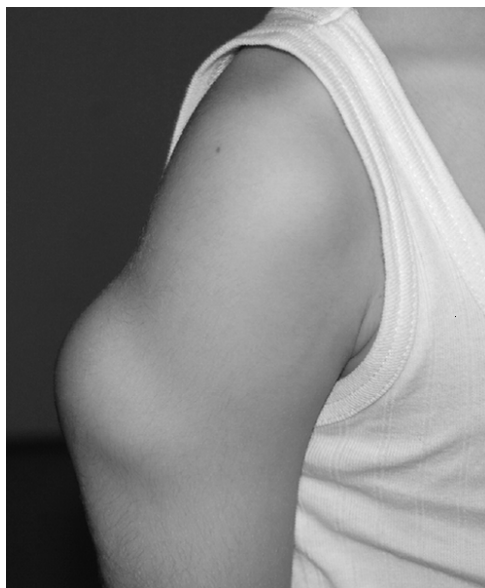
nantly around the knee, are localizations of predilection. Flat bones, vertebrae, and the ribs may also be affected, but the skull is usually not involved. Deformity of the legs, forearms (resembling Madelung deformity) and hands is frequent.

HME should be distinguished from metachondromatosis and the Langer-Giedion syndrome (or the trichorhinophalangeal syndrome type II) and fibrodysplasia ossificans progressiva.

We here describe a 6-year-old boy with an unusually large number of exostosis (18). In addition one of them, in the upper part of humerus, is of giant size.

### *Case report*

A six-year-old boy was found to have multiple osteochondromas on the legs, arms and ribs. The osteochondromas were not present at birth, but occurred after the age of 2 years starting with the forearm. Osteochondromas were further noticed around the knee and the wrists, then on the ribs. Unusually, one of the osteochondromas on the right arm was huge (5 × 6 cm) and painful (Fig. 1). X ray confirmed the benign nature of the osteochondromas. The family history was uneventful as well as the pregnancy and delivery. His intelligence is normal, and ultrasound did not detect any anomalies of the heart or kidneys. He is 134 cm tall (50<sup>th</sup> percentile). In spite of its size and growth, the lesion is so far benign.



*Figure 1 – The forearm with a giant protuberance*

### *Discussion*

Multiple exostoses can be familial or sporadic. Sporadic osteochondroma is approximately six times more common than the HME [2].

The inherited HME is an autosomal dominant disorder classified in 3 types and caused by at least three genes encoding exostosin-1 (EXT1), the gene encoding exostosin-2 (EXT2) and exostosin-3 (EXT3). Several dozens of genetic alterations are reported in those tumour-suppressor genes [3–7]. Mutations of the EXT genes are not detected in all patients [3]. However, recent improvements molecular techniques have decreased the proportion of HME patients without an *EXT1* or *EXT2* mutation to < 15% [2].

Some studies suggested a more severe phenotype (more exostoses, more limb malalignment with shorter limb segments and height, and more pelvic and flatbone involvement) associated with *EXT1* mutations [8], while other studies could not confirm this observation [3].

Pain, functional problems, deformities and disturbance of the blood circulation as a result of blood vessel compression can occur. Additionally, complications of abnormal skeletal growth, shortening of the long bones, restricted range of joint movement, limb length inequalities, depression of the thoracic spinal cord [9], malalignment and longitudinal dystrophy of the fingernails [10] and short stature have been reported. Deformities of the forearm are especially characteristic. Surgery may be required to correct the most severe deformities.

Malignant transformation in secondary peripheral chondrosarcoma is the most severe HME complication occurring in 0.5–5% of patients [11, 12]. Interestingly, malignant transformation seldom occurs before the tenth and after the fiftieth year. The suspicion of secondary chondrosarcoma is indicated by growth of the tumour after puberty and the presence of pain.

### *Conclusion*

We report a boy with an unusually high number of osteochondromas, who in addition, has a giant osteochondroma on the left humerus. A careful follow-up is needed for an early detection of eventual malignant transformation.

### *Consent*

Written informed consent was obtained from the mother of our patient for publication of this case report and any accompanying images. A copy of the written consent is available for review from the Editor-in-Chief of this journal.

*Competing interests*

The authors declare that they have no competing interests.

*Authors' contributions*

All authors participated in diagnosing and writing the article.

## REFERENCES

1. Krooth RS, Macklin MT, Hilbish TF. Diaphysial aklasis (multiple exostoses) on Guam. *Am J Hum Genet.* 1961; 13: 340–7.
2. Bovée JVMG. Multiple osteochondromas. *Orphanet J Rare Dis.* 2008; 3: 3.
3. Jennes I, Entius MM, Van Hulm E, Parra P, Sangiorgi L, Wuyts W. Mutation screening of EXT1 and EXT2 by denaturing high-performance liquid chromatography, direct sequencing analysis, fluorescence in situ hybridization, and a new multiplex ligation-dependent probe amplification probe set in patients with multiple osteochondromas. *Mol Diagn.* 2008; 10(1): 85–92.
4. Francannet C, Cohen-Tanugi A, Le Merrer M, Munnich A, Bonaventure J, Legeai-Mallet L. Genotype-phenotype correlation in hereditary multiple exostoses. *J Med Genet.* 2001; 38(7): 430–4.
5. White SJ, Vink GR, Kriek M, Wuyts W, Schouten J, Bakker B, Breuning MH, den Dunnen JT. Two-color multiplex ligation-dependent probe amplification: detecting genomic rearrangements in hereditary multiple exostoses. *Hum Mutat.* 2004; 24(1): 86–92.
6. Vink GR, White SJ, Gabelic S, Hogendoorn PC, Breuning MH, Bakker E. Mutation screening of EXT1 and EXT2 by direct sequence analysis and MLPA in patients with multiple osteochondromas: splice site mutations and exonic deletions account for more than half of the mutations. *Eur J Hum Genet.* 2005; 13(4): 470–4.
7. Li Y, Wang D, Wang W, Wang J, Li H, Wang J, Wang X, Fu Q. Identification of four novel EXT1 and EXT2 mutations in five Chinese pedigrees with hereditary multiple exostoses. *Genet Test Mol Biomarkers.* 2009; 13(6): 825–30.
8. Alvarez C, Tredwell S, De Vera M, Hayden M. The genotype-phenotype correlation of hereditary multiple exostoses. *Clin Genet.* 2006; 70: 122–30.
9. Quirini GE, Meyer JR, Herman M, Russell EJ. Osteochondroma of the thoracic spine: an unusual cause of spinal cord compression. *Am J Neuroradiol.* 1996; 17: 961–4.
10. Del-Rio R, Navarra E, Ferrando J, Mascaro JM. Multiple exostoses syndrome presenting as nail malalignment and longitudinal dystrophy of fingers. *Arch Dermatol.* 1992; 128: 1655–6.

11. Voutsinas S, Wynne-Davies R. The infrequency of malignant disease in diaphyseal aclasis and neurofibromatosis. *J Med Genet.* 1983; 20: 345–9.
12. Hennekam RC. Hereditary multiple exostoses. *J Med Genet.* 1991; 28: 262–6.

## Резиме

**ГИГАНТСКИ ОСТЕОХОНДРОМ КАЈ МОМЧЕ  
СО МУЛТИПЛИ ЕГЗОСТОЗИ****Кировски И., Гучев З.С., Тасиќ В., Поп-Јорданова Н.***Универзитетска клиника за дејски болести,  
Медицински факултет Скопје, Р. Македонија*

Хердитарна мултипла егзостоза е наследна автосомна доминантна болест која се карактеризира со присуство на мултипли егзостози – бенигни картилагинозни тумори. Прикажуваме 6-годишно момче со невообичеано голем број егзостози (18), од кои еден од нив во пределот на десниот хумерус е огромен (5 × 6 cm) и предизвикува болка. Со рендгенографија е потврдена бенигна природа на остеохондром. Фамилијарната историја, бременоста и породувањето се без особености. Пациентот е со нормална интелигенција, со ехо преглед не се детектираа аномалии на срцето односно на бубрезите. Постојење на голем остеохондром кај младо момче е реткост. Се наметнува потребата за редовно следење на пациентот со цел навремено да се детектира евентуална малигна трансформација.

**Клучни зборови:** Мултипли хердитарни егзостози, гигантски остеохондром.

**Corresponding Author:**

**Prof. D-r Nada Pop-Jordanova**  
**University Children's Hospital**  
**Medical Faculty Skopje**  
**R. Macedonia**

**E-mail: npopjordanova@gmail.com**