

PRESERVATION OF THE VEGETATIVE PELVIC NERVES AND LOCAL RECCURENCE IN THE OPERATIVE TREATMENT OF RECTAL CANCER

Jota Gj.,¹ Karadzov Z.,¹ Panovski M.,¹ Vasilevski V.,¹ Serafimoski V.^{1,2}

*¹Digestive Surgery Clinic, Clinical Centre, Medical Faculty,
Ss. Cyril and Methodius University, Skopje, R. Macedonia*

^{1,2}Macedonian Academy of Sciences and Arts, Skopje, R. Macedonia

Abstract: Life quality of the patients operated from rectal cancer is a serious problem.

Despite the curing as a primary objective in the treatment of the rectal cancer, special attention is paid to the life quality upon the performed operation on the subjected patients. The analyzed series consists of 29 patients with rectal cancer, operated on at the Digestive Surgery Clinic within the framework of the Clinical Centre in Skopje, in the period between 2001–2006. Our series involves patients from the T2 and T3 stage of the illness, where it possible to preserve the vegetative pelvic nerves, that are characterized by a relatively long-lasting symptomatology and relatively high percentage of lymphatic metastases.

The standardization of the operative intervention resulted in an increase in the number of patients with continuous operations and preservation of the neuro-vegetative plexus without influencing the radicalism of the intervention. The application of the Stapler and Double Stapler technique brought about an increase in the number of continuous operations characterized by a termino-terminal colorectal anastomosis. On the other hand the preventive creation of LOOP ileostomies in the case of the ultra low resections resulted in a decrease in the level of dehiscence of this type as one of the most common and most difficult complications.

The preservation of the pelvic neuro-vegetative plexus prolongs the operation time by 30 to 60 minutes, depending on the case and the patient. We assume that the procedure does not have a particular influence on the frequency of the complications,

and at the same time it positively affects the revival of the urinal and sexual function. Taking into consideration the fact that the lymphatic dissection increases the possibility of removal of the malignant tissue and enables an adequate "staging" and on the other hand the preservation of the pelvic plexus improves the quality of life, both in terms of the sexual function and the function of the urinary bladder, it is recommended that this way of treatment becomes an integral part in the surgical treatment of the rectal cancer.

Key words: rectal cancer, pelvic neuro-vegetative plexus, quality of life, local recurrence.

Introduction

The most common localization of metastatic deposits in the case of rectal cancer occurs in the lateral group of lymphatic glands around the *a.rectalis media* in 14% of cases. In those cases where the tumor penetrates the entire wall of the rectum, this percentage of metastatic deposits increases up to 20% (Mascagni D., 1992). This high incidence of lymphatic metastases in a region that is not involved in the conventional resection justifies the radical approach (Moriya Y., 1998).

A number of Japanese authors present a significant improvement in the survival and decrease in the loco-regional recrudescence in the case of patients with radical lymphatic dissection (Hojo K., Moriya Y., 1998).

Heald describes the possible mechanisms during loco-regional recurrence existence.

- ◆ direct spread into mesorectum – *lateral or radial spread*,
- ◆ implantation of exfoliative cells or tumor cells seeding due to tumor cutting,
- ◆ intramural *aboral* expansion,
- ◆ direct spreading of the levatories.

Stearns differentiates two types of loco-regional recurrence:

Perineal, which appearance results from the inadequate perineal resection or the implementation of the cancerous cells into the perineal wound.

Pelvic, recurrence, resulting from the unextirpated positive lymph nodes or postoperative residual tissue existence.

The performance of the lymphatic dissection in the treatment of the rectal cancer results in a higher risk of sexual and urinary disorders in these patients due to unintentional damage of the pelvic autonomic nerves responsible for the function of the urinary bladder and the male sex organs. Due to this occurrence, the extensive lymphadenectomy is justified in the case of high-risk

patients of presence of metastatic deposits in the regional lymphatic glands (Hojo K., 1998).

In the performance of the pelvic lymphadenectomy, the damage of the pelvic neuro-vegetative plexus can occur on the following five localizations:

- The ligation place on the *a.mesenterica inferior* next to the aorta where the pre-aortic sympathetic plexus can be damaged;
- The mobilization part of the sacral mesorectum that can injure the pre-sacral sympathetic hypo-gastric plexus;
- The lateral dissection part along the length of the lateral pelvic wall that can damage the hypo-gastric nerve and the plexus that carries sympathetic and para-sympathetic nerves;
- The place of the extremely lateral separation of the lateral ligaments that cause damage on the *nn.erigentes*;
- The place of the anterior perineal dissection that damages the *nn.erigentes* situated in the capsule of the prostate and around the seminal vesicles.

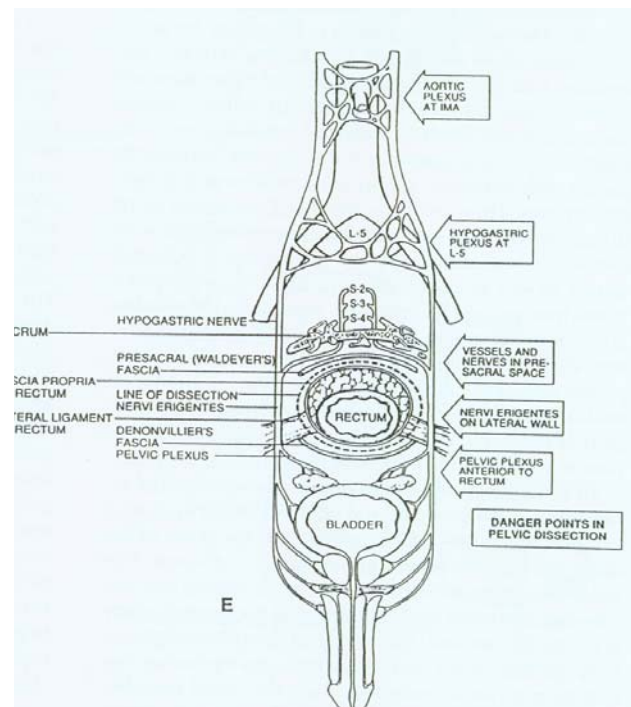


Figure 1 – Danger points in pelvic dissection

Слика 1 – Rizični mesta pri pelvi~nata disekcija

It is almost impossible to perform a TEM and preserve the hypo-gastric neural plexus and perform a dissection of the lymphatic glands around the *a.iliaca interna* without damaging the pelvic plexus. In the case of an advanced rectal cancer, it is possible to preserve the urinary and to a certain level the sexual function by means of selective preservation of the S 4 pelvic nerve.

Material and Methods

A total number of 29 patients suffering from rectal cancer in the T2 and T3 stage without distant metastases have been treated, who have been operated at the Digestive Surgery Clinic within the framework of the Clinical Centre in Skopje, in the period from 01.01.2001 to 15.01.2006. Among them 16 (55.17%) were men, and 13 (54,83%) were women. The average age of the group was 58.9 years (minimum 52, maximum 68).

Adenocarcinoma of the rectum was preoperatively diagnosed in all patients by means of clinical check-up, irrigography, endoscopy with biopsy as well as CT of the abdomen. By examining the patients the factual preoperative state of the urinary and sexual function (erectile and ejaculatory) was ascertained and the possible presence of rest-urine was determined.

On the basis of the preoperative "staging" of the tumor, a radical operation was indicated in the T2 and T3 stage as well as suspected metastases in the regional lymphatic glands. All of them have undergone curative surgical procedures that involve regional lymphatic dissection by preservation of the pelvic neuro-vegetative plexus. A continuous operation (front low or ultra low resection of the rectum) was performed on 19 (65.51%) of the patients, whereas only 5 patients (17.24%) underwent abdominal perineal resection of the rectum depending on the distance of the tumor from the anal brim. A total of 370 lymphatic glands have been isolated, that is to say 15.41 lymphatic glands from each patient. The level of invasion of the primary tumor as well as the presence of metastatic deposits in the lymphatic glands have been determined by means of microscopic examination at the Oncology and Radiology Institute within the framework of the Clinical Centre in Skopje.

In the postoperative period, the patients were questioned regarding the probable change in the urinary and sexual function.

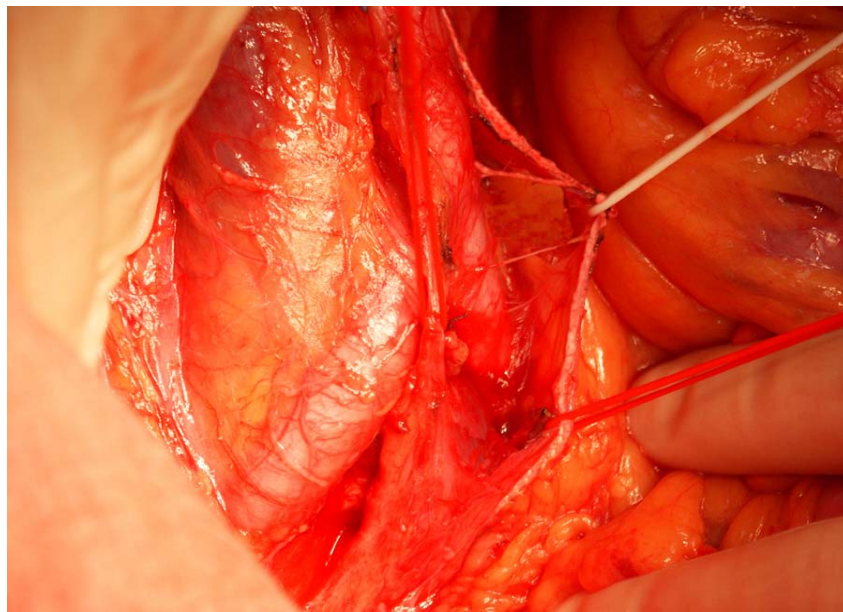


Figure 2 – Preservation of pelvic nerves
Слика 2 – Презервација на њелвички нерви

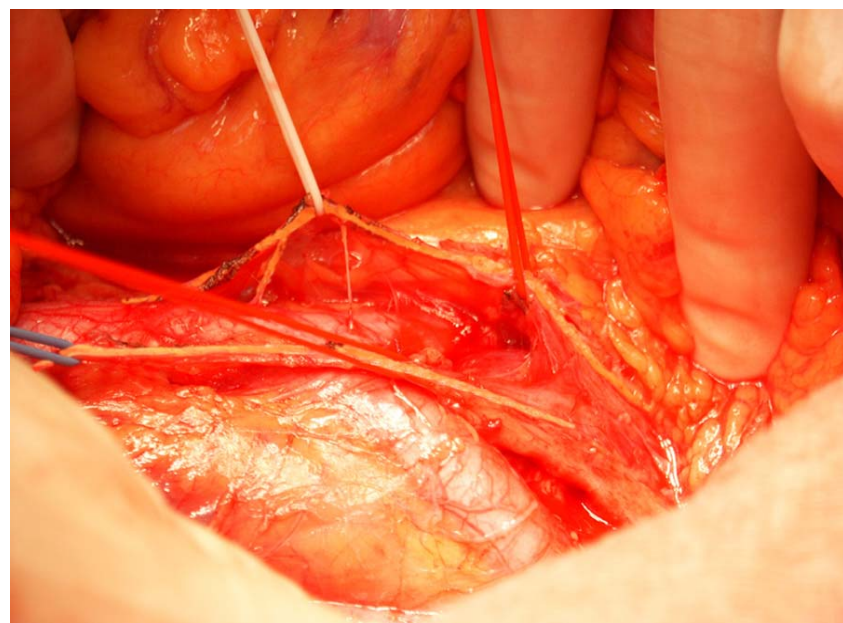


Figure 3 – Preservation of pelvic nerves
Слика 3 – Презервација на њелвички нерви

Results

The 24 subjects involved in the examination had been operated of rectal cancer at the Digestive Surgery Clinic in the period from the year 2001 to January 2005.

The predominant symptoms that characterize the subjects of our group were the following: blood in the stool found in 27 patients (93.1%) and irregular stools found in 22 patients (75.86%). The duration of the disorders in the major number of patients was up to 6 months and it was evident in 16 patients (55.17%). Evidence of disorders exceeding 12 months was found in 11 patients (37.93%). The tumors that are 10–15 cm away from the anal brim are dominant in terms of the localization of the tumor.

Regarding the penetration of the tumor in the layers of the wall of the large intestine, the dominant tumors are those of the T3 stage, i.e. those penetrating the subserous layer of the wall of the large intestine, evident in 19 patients (65.51%).

Metastatic deposits in the regional lymphatic glands were found in 6 patients (20.6%). With respect to the degree of penetration of the tumor and the presence of lymphogenic metastases, the correlation – increase in the percentage of lymphogenic metastases by increase in the extent of the penetration may exist. According to Dukes classification, 3 cases (10.34%) have been classified in A stage, 20 cases (68.96%) in B stage while 6 cases (20.68%) have been classified in C stage.

19 patients have undergone continuous operations of the type of front low or ultra low resection of the rectum (79.1%), while 5 patients have undergone abdominoperineal resection of the rectum (20.9%). 18 patients have undergone anastomosis applying the Stapler technique, while only 1 patient has undergone a manual anastomosis. The average stay in the clinic was 13.4 days and the duration of the postoperative stay was 9.93 days.

The analysis of the urinary function in the postoperative period indicated a slight deterioration of the same in the form of diuretic disorders and rest-urine (200 ml) evident in 3 patients (10.34%), while only one patient indicated an extended catheterization of 2 weeks. The analysis of the sexual function, i.e. the erectile and ejaculatory function of the patients of the male gender, indicated a slight deterioration of the erectile function only in 2 patients. The state of only one of them did not improve by the end of the sixth month.

This research has shown that within the first postoperative year the locoregional recurrence appeared in two patients (6.89%), while the recto-vaginal fistula was noticed with one patient as a result from the postoperative X-ray radiation.

Discussion

Despite the perfection of the surgical technique, the surgical treatment of the rectal cancer poses a major challenge for the surgeon in his determination to attain a high percentage of healing and at the same time to provide these patients with a quality life.

The diagnosis of the patients suffering from rectal cancer in a relatively advanced stage (large tumors, T3 and T4 as well as the presence of metastatic deposits in the regional lymphatic glands) in the Republic of Macedonia, justifies the application of radical surgical interventions in the treatment of the rectal cancer.

Some authors have abandoned this technique with the explanation that the less radical operations are evenly as effective (Glass R. E., Ritchie J. K., Thompson H. R. 1995). Some series prove that there is no difference in the occurrence of the loco-regional relapse in those patients with or without a loco-regional lymphatic dissection (Enker W. E. 2002). On the other hand, a major number of Japanese authors indicate a significant improvement in the survival and decrease in the loco-regional relapse in patients with radical lymphatic dissection (Hojo K., Moriya Y. 1998). These extensive surgical procedures were introduced at the Digestive Surgery Clinic within the framework of the Clinical Centre more than 15 years ago. The negative consequences on the urinary function as well as the erectile and ejaculatory function are significantly more pronounced in these operations. The complete preservation of the autonomic pelvic plexus is the best possible way to prevent these harmful and undesirable consequences (Maas C. P., Moriya Y. 1998).

In order to perform the lymphatic dissection it is necessary to identify and preserve the vegetative nerves in the first place by application of a sharp dissection using a pair of scissors. This procedure extends the duration of the operation by 30 to 60 minutes. It is almost impossible to perform a total mesorectal excision and preserve the hypo-gastric plexus, perform a lymphatic dissection of the *a. iliaca interna* without damaging the pelvic nervous plexus, i.e. it is impossible to preserve the pelvic autonomic plexus completely in the case of patients with advanced rectal cancer. However, while performing the pelvic lymphatic dissection it is possible to preserve the urinary, and at times the sexual function by means of selective preservation of the S4 nerve.

The application of this procedure in our series indicated a slight deterioration of the urinary function in the form of diuretic disorders (burning, urine that is of unpleasant smell or clouded) and rest-urine of 200 ml in only 3 patients (10.34%), while only one patient indicated an extended catheterization in duration of 2 weeks.

The analysis of the sexual function, i.e. the erectile and ejaculatory function of the patients of the male gender, indicated a slight deterioration of the erectile function in only 4 patients (13.79%). The state of only one of them did not improve by the end of the sixth month. Enker attested a reduced potency in 13.3% of cases and disturbed potency in 12.1% of cases in one of his series involving 38 patients with low resection of the rectum. The preservation of the upper hypo-gastric plexus is crucial for the ejaculatory function, while the preservation of the pelvic plexus is important for the preservation of the erectile function. The preservation of the pelvic neuro-vegetative plexus diminishes the morbidity and yields satisfactory functional results and is recommended as a standard operative procedure in the case of rectal cancer (Maas C. P., Moriya Y. 1998).

Conclusion

The investigation into our series as well as the results derived from a number of other series suggest that it is possible to preserve the neuro-vegetative pelvic plexus. The preservation of the neuro-vegetative plexus does not affect the radicalism of the operative procedure, expressed by the number of extirpated lymphatic glands, i.e., the extension of the lymphatic dissection as a constituent part of the oncologic procedure.

The preservation of the neuro-vegetative plexus positively affects the quality of life of the patients with rectal cancer, expressed by the sexual function and the function of the urinary bladder.

REFERENCES

1. Beets-Tan R., Beets G., Vliegen R. *et al.* (2001): Accuracy of magnetic resonance imaging in prediction of tumor-free resection margin in rectal cancer surgery. *Lancet*; 357: 497–504.
2. Hanna N. N., Guillem J., Dosoretz A., Stickwoman E., Minsky B. D., Cohen A. M. (2001): Intraoperative parasympathetic nerve stimulation with tumescence monitoring during total mesorectal excision. *Ann Surg*; 203: 426–433.
3. Havenga K., Enker W. E. (2002): Autonomic nerve preserving total mesorectal excision. *Surg Clin North Am*; 82: 1009–18.
4. Havenga K., Maas C. P., De Ruiter M. C., Welvaart K., Trimbos J. B. (2000): Avoiding long-term disturbance to bladder and sexual function in pelvic surgery, particularly with rectal cancer. *Semi Surg Oncol Apr-May*; 18: 3 235–43.
5. Hojo K., Vernava A. M., Sugihura K., Katumata K. (1998): Preservation of urine-voiding and sexual function after cancer surgery. *Dis Colon Rectum*; 34: 532–539.

6. Jeffery G. M., Hickey B. E., Hider P. (2002): Follow-up strategies for patients treated for non-metastatic colorectal cancer. *Br J Surg*; 72: 599–601.
7. Junginger T., Kneist W., Heintz A. (2003): Influence of identification and preservation of pelvic autonomic nerves in rectal cancer surgery on bladder dysfunction after total mesorectal excision. *Dis Colon Rectum*; 46: 621–8.
8. Kim N. K., Aahn T. W., Park J. K. *et al.* (2002): Assessment of sexual and voiding function after total mesorectal excision with pelvic autonomic nerve preservation in males with rectal cancer. *Dis Colon Rectum*; 45: 1178–85.
9. Maas C. P., Moriya Y., Steup W. H., Kiebert G. M., Kranenbarg W. M., Van de Velde C. J. (1998): Radical and nerve-preserving surgery for rectal cancer in The Netherlands: a prospective study on morbidity and functional outcome. *Br J Surg. Jan*; 85: 192–7.
10. Mac Farlane J. K., Ryall R. D., Heald R. J. (1993): Mesorectal excision for rectal cancer. *Lancet*; 341: 457–460.
11. Mascagni D., Hojo K., Moriya Y. (1992): Pattern of lymph node metastasis from low rectal cancer. *Dis Colon Rectum*; 35: P6.

Резиме

ПРЕЗЕРВАЦИЈА НА ПЕЛВИЧНИОТ ВЕГЕТИВЕН СПЛЕТ И ЛОКАЛЕН РЕЦИДИВ ВО ОПЕРАТИВНИОТ ТРЕТМАН НА РЕКТАЛНИОТ КАРЦИНОМ

Јота Ѓ.,¹ Карацов З.,¹ Пановски М.,¹ Василевски В.,¹ Серафимоски В.^{1,2}

¹Клиника за дигестивна хирурџија, Клинички центар, Медицински факултет, Универзитет „Св. Кирил и Методиј“, Скопје, Р. Македонија

²Македонска академија на науките и уметностите, Скопје, Р. Македонија

Покрај куративноста како основна цел во третманот на ректалниот карцином посебно внимание се посветува и на квалитетот на живот по оперативниот зафат кај овие болни. Анализираниот серија се состои од 24 пациенти со ректален карцином оперирани на Клиниката за дигестивна хирургија, при Клиничкиот центар во Скопје, во периодот од 2001 до 2005 година. Во нашата серија се вклучени пациенти од Т2 и Т3 стадиум од болеста кај кои е можна презервација на невровегетативниот пелвичен сплет, која се карактеризира со релативно долготрајна симптоматологија и релативно висок процент на лимфогени метастази.

Со стандардизирање на оперативната постапка се зголеми бројот на пациенти со континуитетни операции и презервација на невровегетативниот плексус без тоа да влијае на радикалитетот на постапката. Со употреба на

Stapler i Double Stapler техниката се зголеми бројот на континуитетни операции со термино-терминална колоректална анастомоза. Од друга страна, пак, со превентивното креирање на LOOP илеостоми кај ултраниските резекции се намали степенот на дехисценции кај овој тип на операции како една од најчестите и најтешките компликации.

Презервацијата на пелвичниот невровегетативен плексус го продолжува времето на операција за 30 до 60 минути зависно од случајот и хирургот. Сметаме дека таа постапка нема посебно влијание врз зачестеноста на компликациите, а истовремено има позитивен ефект врз зачувувањето на уринарната и сексуалната функција на живот кај овие болни. Имајќи предвид дека лимфната дисекција ја зголемува можноста за отстранување на туморското ткиво и овозможува адекватен "staging", од друга страна, пак, со презервацијата на пелвичниот плексус се подобрува квалитетот на живот како на сексуалната функција така и на функцијата на мочниот меур, овој начин на третман се препорачува да стане составен дел во хируршкиот третман на ректалниот карцином.

Клучни зборови: карцином на ректум, пелвичен невровегетативен плексус, квалитет на живот, локален рецидив.

Corresponding Author:

Jota Gj.
Digestive Surgery Clinic,
Medical Faculty,
Ss. Cyril and Methodius University,
Skopje, R. Macedonia

Tel: 02 3130 104
Mob: 075 455 100